

# Successful Management of Post-Infarction Ventricular Septal Rupture: A Case Report

Paulus Alfredo, MD<sup>1</sup>, Muhammad Fauziar Ahnaf Mumtazar, MD<sup>1</sup>, Pipin Ardianto, MD<sup>1</sup>, Safir Sungkar, MD<sup>1</sup>, Ilham Uddin, MD<sup>1</sup>, Sahal Fatah, MD<sup>2</sup>, Sefri Noventi Sofia, MD<sup>1\*</sup>

<sup>1</sup> Department of Cardiology and Vascular Medicine, Faculty of Medicine, Diponegoro University – Dr. Kariadi General Hospital Semarang, Indonesia.

<sup>2</sup> Department of Surgery, Faculty of Medicine, Diponegoro University – Dr. Kariadi General Hospital Semarang, Indonesia.

Received 16 May 2024; Accepted 28 July 2024

## Abstract

**Background:** Post-infarction ventricular septal rupture (PIVSR) is a rare but severe mechanical complication of myocardial infarction (MI) associated with a high mortality rate. Hemodynamic instability is inevitable both during the progression of the condition while awaiting timely surgical intervention and in the postoperative period. Continuous hemodynamic monitoring can enhance the observation of a patient's circulatory status, facilitate prompt and targeted interventions, and ultimately improve prognosis.

**Case Presentation:** A 65-year-old man presented with dyspnea 19 days after the onset of MI. He was referred to our hospital with symptoms of acute heart failure and a grade IV/VI pansystolic murmur audible at the apex. Echocardiography revealed a 14 mm ventricular septal defect at the apical region, accompanied by a left-to-right shunt. The patient was stabilized in the cardiovascular care unit and scheduled for ventricular septal rupture (VSR) closure and coronary artery bypass grafting. The procedure was performed on the 16th day of hospitalization. Postoperatively, the patient developed shock due to bleeding and cardiac tamponade, necessitating 2 redo surgeries. Despite these complications, the patient ultimately survived following extensive stabilization efforts.

**Conclusion:** Hemodynamic monitoring and stabilization are critical factors in determining the prognosis of patients with PIVSR. Timely diagnosis of postoperative complications that compromise hemodynamics, combined with a collaborative interdisciplinary team approach, can enhance treatment strategies, significantly reduce fatal complications and morbidity, and ultimately improve the patient's likelihood of survival.

*J Teh Univ Heart Ctr* 2024;19(S1):63-67

**This paper should be cited as:** Alfredo P, Mumtazar F, Ardianto P, Sungkar S, Uddin I, Fatah S, et al. Successful Management of Post-Infarction Ventricular Septal Rupture: A Case Report. *J Teh Univ Heart Ctr* 2024;19(S1):63-67. DOI: [10.18502/jthc.v19is1.18480](https://doi.org/10.18502/jthc.v19is1.18480)

**Keywords:** Myocardial infarction; Ventricular septal rupture; Hemodynamic

\*Corresponding Author: Sefri Noventi Sofia, Diponegoro University, Semarang, Indonesian. Email: [sefrinoventisofia@gmail.com](mailto:sefrinoventisofia@gmail.com).



## Introduction

Post-infarction ventricular septal rupture (PIVSR) is a major mechanical complication resulting from acute myocardial infarction (MI) and is associated with a poor prognosis.<sup>1</sup> With the development of acute reperfusion techniques for MI, the incidence of PIVSR has declined, and it is now identified earlier in the post-MI course. Despite significant advancements over the past 2 decades in reducing overall mortality rates for patients with acute MI, the prognosis for those who develop PIVSR remains grim.<sup>2</sup> Even for patients who survive this severe complication, the long-term outlook continues to be unfavorable.<sup>3</sup>

Despite the availability of various treatment options, such as cardiac assist devices, surgical interventions, and interventional closures, the mortality rate for PIVSR remains significantly high.<sup>4</sup> Studies have shown that the survival rate for patients with PIVSR who do not undergo surgery is less than 10% after 1 month. Surgical intervention, nonetheless, can significantly improve outcomes for this condition. While surgery plays a crucial role, postoperative mortality rates remain elevated, and the optimal timing for surgical intervention continues to be a topic of debate.<sup>5</sup>

## Case Presentation

A 65-year-old man was referred to our hospital with a primary complaint of shortness of breath that had persisted for 7 days prior to admission. He reported a history of typical chest pain 19 days before admission, described as a heavy, crushing sensation in the chest that radiated to his left arm and back. The pain did not improve with rest and was accompanied by nausea, vomiting, and cold sweats. On auscultation, rales and rhonchi were audible in both lungs, along with a harsh grade IV/VI pansystolic murmur. The murmur was most prominent at the apex and radiated to the lower sternal border, accompanied by a thrill. An ECG

revealed ST-segment elevation in leads V<sub>2</sub>-V<sub>6</sub> and pathological Q waves in the same leads (Figure 1). The troponin level was elevated at 3.06 µg/L, and a chest X-ray revealed signs of pulmonary edema, pneumonia, and pleural effusion. Transthoracic echocardiography (TTE) identified a 14 mm apical ventricular septal rupture (VSR) with a left-to-right shunt and a reduced left ventricular ejection fraction of 35.9% (Figure 2).

The patient was admitted to the cardiovascular care unit (CVCU) for stabilization and surgical preparation. During hospitalization, he developed cardiogenic shock, which was successfully stabilized to allow further management. On the 15th day, an intra-aortic balloon counterpulsation (IABCP) device was placed, and coronary angiography was performed in preparation for the next steps. The coronary angiogram demonstrated subtotal occlusion with haziness and a grade IV thrombus in the proximal left anterior descending artery, along with 95% proximal stenosis (Figure 3). On the 16th day, the patient underwent VSR closure and coronary artery bypass grafting with a single graft to the left anterior descending artery (Figure 4).

A few hours after surgery, the patient experienced hemodynamic instability and continuous output from the water seal drainage, indicating a massive hemorrhage. An emergency redo operation was performed, and bleeding from the left ventricle was successfully corrected. Three days later, another episode of hemodynamic instability occurred. A bedside TTE examination showed a large blood clot compressing the right atrium, prompting a second emergency redo operation to remove the clot (Figure 5).

Following the surgical procedure, the patient continued to experience ongoing hemodynamic instability and developed additional complications, including worsening renal function, sepsis, and arrhythmia. These issues were stabilized in the CVCU. Inotropic and vasopressor support was gradually down-titrated and eventually discontinued as the patient's clinical condition improved. After a total of 30 days in the CVCU, the patient was transferred to the ward for further recovery.

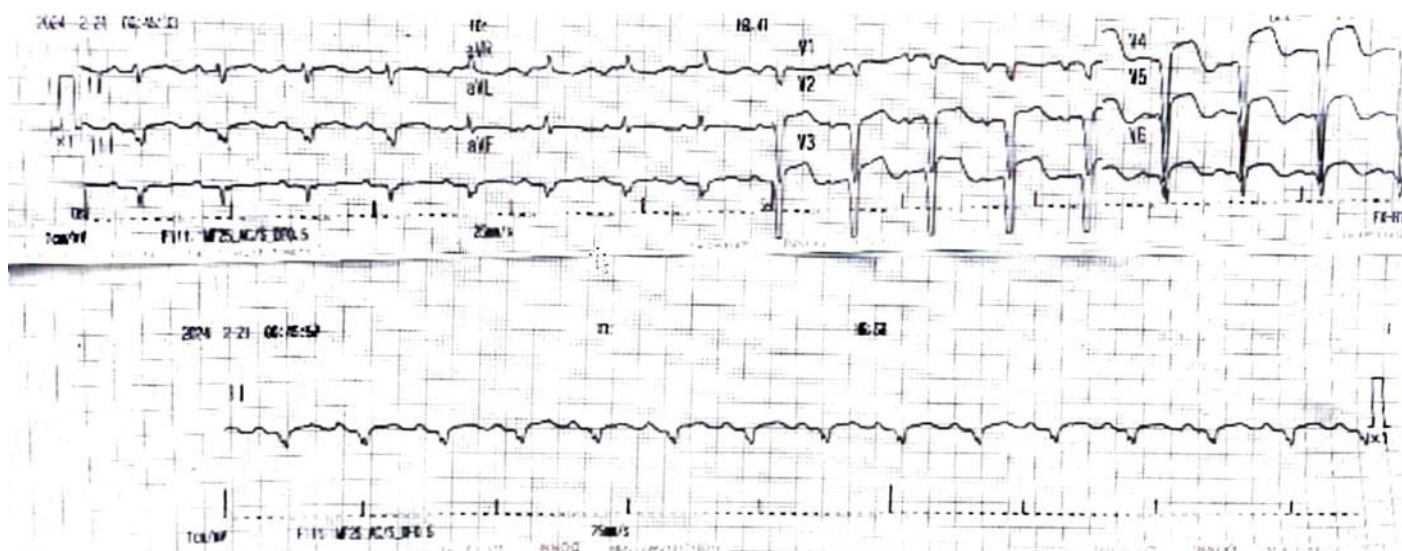


Figure 1. ECG on admission shows Q waves and ST-segment elevation in the anterior leads.

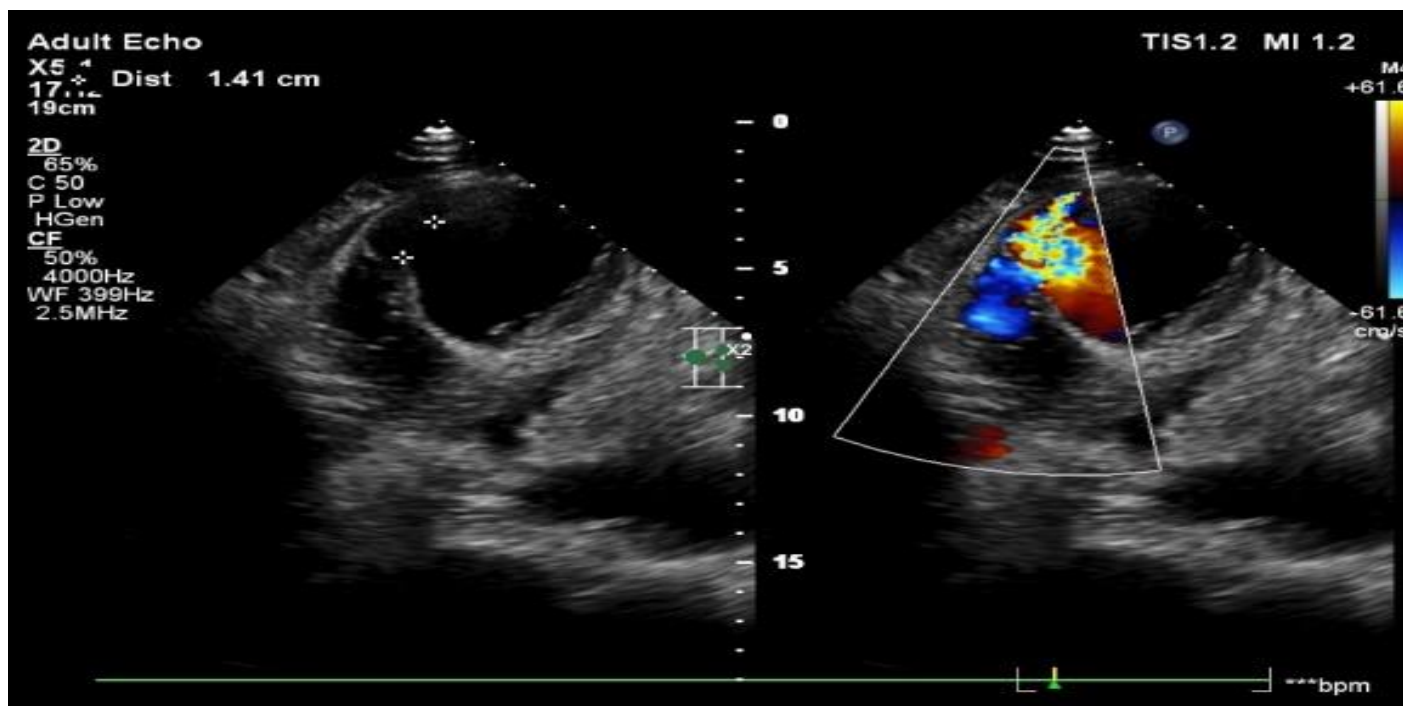


Figure 2. Bedside echocardiography reveals an apical ventricular septal rupture measuring 14 mm.

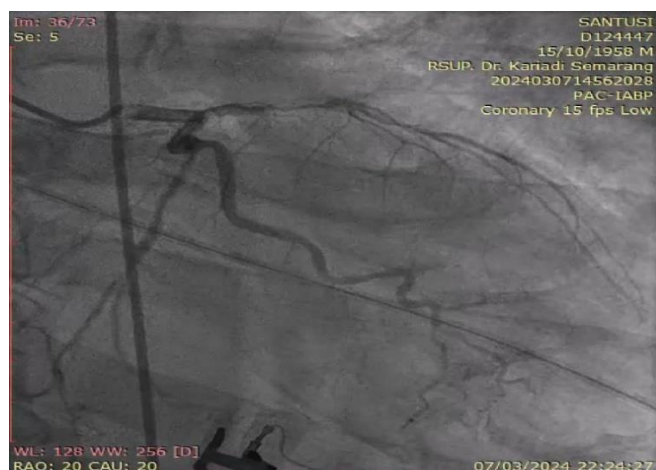

Figure 3. Coronary angiography demonstrates subtotal occlusion in the proximal left anterior descending artery

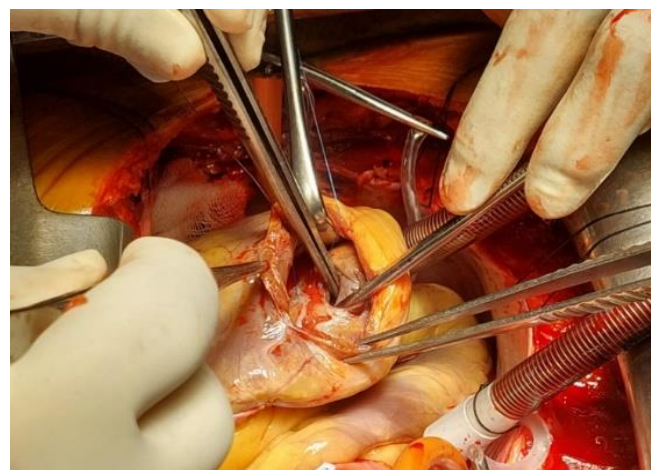

Figure 4. A ventricular septal rupture was identified during surgery.

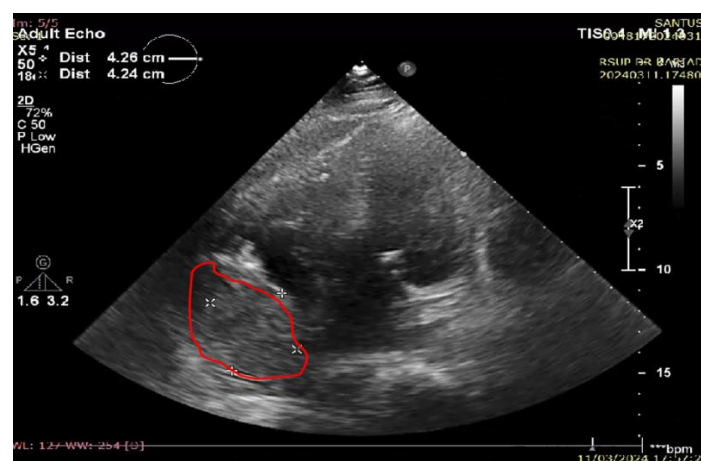


Figure 5. The transthoracic echocardiogram shows a large blood clot compressing the right atrium. The red areas indicate the thrombus within the pericardial sac that is pressing against the right atrium.





## Discussion

VSR is primarily caused by a full-thickness (transmural) MI in one of the coronary arteries. Nevertheless, several case reports have suggested that it can also be triggered by partial-thickness infarctions, such as non-ST elevation MI or unstable angina.<sup>6</sup> The condition is largely attributed to physical shear stresses, particularly at the junction between the infarcted area and the healthy myocardium. This mechanism is also associated with complications such as ventricular aneurysm, free wall rupture, or papillary muscle rupture.<sup>7</sup>

Following the development of VSR, a connection forms between the right and left ventricles. This allows oxygenated blood to shunt from the high-pressure left ventricle to the low-pressure right ventricle. The onset of VSR after MI is rapid, and the condition follows a progressive course, with a mortality rate exceeding 90% within the first year. This poor prognosis is primarily due to the sudden volume overload imposed on both ventricles, which are already compromised by a significant MI. In addition, the patient may present with concurrent complications such as ventricular pseudoaneurysm or mitral valve insufficiency, both of which can further impair ventricular function. Only a limited number of cases have documented patient survival following medical therapy alone.<sup>6, 7</sup>

Pharmacological intervention should be initiated to achieve hemodynamic stability in patients with VSR. The primary goals include reducing cardiac afterload and increasing forward cardiac output. Vasodilators can mitigate the left-to-right shunt caused by the mechanical defect, improving cardiac output. Intravenous nitroglycerin, for instance, acts as a vasodilator and may enhance myocardial blood flow in patients with significant ischemic heart disease.<sup>6</sup> When used alone, inotropic agents can improve cardiac output. Still, without changes in the pulmonary-to-systemic flow ratio (Qp/Qs ratio), they significantly increase left ventricular workload and myocardial oxygen demand. In cases of severe cardiogenic shock, vasodilator therapy may be insufficient, often necessitating the addition of vasopressor support.<sup>6</sup>

Vasopressors significantly increase left ventricular workload and myocardial oxygen consumption. They also have the potential to raise systemic afterload, which can elevate the Qp/Qs ratio, ultimately reducing cardiac output and further increasing myocardial oxygen demand.<sup>6</sup>

The use of IABCP is a critical intervention for temporary hemodynamic support. IABCP lessens left ventricular afterload, leading to an increase in overall cardiac output and a decrease in the Qp/Qs ratio. Moreover, IABCP enhances diastolic augmentation, thereby improving coronary blood flow and oxygen supply to the myocardium.<sup>2, 6</sup>

In cases of cardiogenic shock, it is crucial to emphasize that IABCP should not be considered a substitute for immediate intervention. Mortality in patients with VSR is not primarily due to heart failure but rather to end-organ failure. The risk of death can only be reduced by minimizing the duration of shock.<sup>2, 6</sup>

Attaining hemodynamic stability before surgery is highly beneficial; however, prolonged efforts to improve the patient's hemodynamic status can be risky. While this

aggressive approach often results in temporary stabilization of critically ill patients, the benefits are typically short-lived, and rapid deterioration may follow. Therefore, timely diagnosis and prompt surgical intervention are essential. Approximately 10% to 15% of patients can be successfully managed with conservative measures for 2 to 4 weeks, after which surgical intervention can be performed with significantly reduced risk.<sup>8</sup>

In a prior study, the mortality rate among patients showed significant variation depending on the timing of the surgical procedure. Patients who had surgery within 7 days of presentation experienced a mortality rate of 54.1%, while those who delayed the repair beyond 7 days had a mortality rate of 18.4%. The highest mortality rate, at 60%, was observed in individuals who underwent surgery within the first 24 hours.<sup>9</sup> After 3 to 4 weeks of medical optimization with inotropic and mechanical cardiac support, surgery may be considered if the patient's hemodynamics remain stable. The potential link between delayed surgery and improved outcomes may be due to the progression of the infarct and the enhanced stability of the cardiac tissue, which allows for a more effective repair. However, it is crucial to recognize that this outcome may also be affected by survival bias, as early surgery is generally performed on patients with significant hemodynamic instability and compromised circulation.<sup>2, 9</sup>

Current research indicates that while surgical mortality rates remain high, non-surgical mortality rates are even more significant. Clinicians must, therefore, weigh the known risks of immediate surgical intervention against the uncertain risks of delaying surgery and potential clinical deterioration.

This paper outlines a streamlined multidisciplinary approach to managing these patients, underscoring the significance of a customized strategy for each individual case.<sup>2, 6</sup>

## Conclusion

PIVSR is a life-threatening condition associated with a high mortality rate. Early surgical intervention often results in higher death rates due to the difficulty of securing sutures in fragile, necrotic tissue. Conversely, a delayed approach allows for fibrosis to develop, making suturing more feasible. Patients presenting with cardiogenic shock also face a significantly elevated risk of mortality. Additional poor prognostic factors include advanced age, multiorgan failure, and a high New York Heart Association (NYHA) functional class. The patient's clinical condition at the time of surgery is crucial to determining the adverse outcomes associated with PIVSR.

Undoubtedly, most patients present with unstable hemodynamics, ranging from severe pulmonary edema to cardiac arrest. Other concurrent poor prognostic factors, such as VSR size, infarct size, and biventricular dysfunction, may further exacerbate the adverse effects of hemodynamic instability on patient survival. Effective hemodynamic management and stabilization are critical in determining the prognosis of PIVSR during the perioperative period. Timely diagnosis of complications that worsen hemodynamics, combined with a collaborative interdisciplinary team

approach, can enhance treatment strategies, significantly reduce fatal complications and morbidity, and ultimately improve the patient's chances of survival.

## References

1. Zhang XY, Bian LZ, Tian NL. The Clinical Outcomes of Ventricular Septal Rupture Secondary to Acute Myocardial Infarction: A Retrospective, Observational Trial. *J Interv Cardiol*. 2021 Dec
2. Suryono S, Naesilla N, Roestanajie J, Ariyanti D, Wulandari P. Ventricular Septal Rupture in ST-Elevation Myocardial Infarct in Low Resource Setting: A Case Series. *Indonesian J Cardiol*. 2020;41:226-236
3. Tripathi A, Bisht H, Arya A, Konat A, Patel D, Patel J, Godhani D, Mozumder K, Parikh D, Jain P, Sharma K. Ventricular Septal Rupture Management in Patients With Acute Myocardial Infarction: A Review. *Cureus*. 2023 Jun 13;15(6):e40390. doi: 10.7759/cureus.40390. PMID: 37456418; PMCID: PMC10345166.
4. Ma D, Zhang Z, Zhang S, Wang Z, Zhang G, Wang C, Xi J. Treatment Strategies for Ventricular Septal Rupture After Myocardial Infarction: A Single-Center Experience. *Front Cardiovasc Med*. 2022 Feb 22;9:843625.
5. Ronco D, Matteucci M, Kowalewski M, Bonis MD, Formica F, et al. Surgical Treatment of Postinfarction Ventricular Septal Rupture. *JAMA Netw Open*. 2021;4(10):e2128309.
6. Damluji AA, Diepen S, Menon V, Tamis-Holland JE, Bakitas M. Mechanical Complications of Acute Myocardial Infarction: A Scientific Statement From the American Heart Association. *AHA Circulation*. 2021; 144:e16-e35.
7. Hermawati IE, Rahman GM, Huda MF, Mahardina R, Mahardhika R, et al. Long-Term Survival of Ventricular Septal Rupture (VSR) Closure Concomitant with CABG in Post-Acute Myocardial Infarction Patient. *Cardiovascular Cardiometabolic Journal* (2020); 2: 50-56
8. Giblett JP, Jenkins DP, Calvert PA. Transcatheter treatment of postinfarct ventricular septal defects. *Heart* 2020;106:878-884.
9. Papalexopoulou N, Young CP, Attia RQ. What is the best timing of surgery in patients with post-infarct ventricular septal rupture? *Interact Cardiovasc Thorac Surg*. 2013 Feb;16(2):193-6.