

Photo Clinic**Successful Reattempt of Percutaneous Balloon Mitral Valvotomy Using Reverse-Loop Entry Technique**Sriram Veeraraghavan ^{1*}, Bharath Raj Kidambi ², Sandeep Unnikrishnan ³, Karthikeyan Balakrishnan ⁴¹ Department of Cardiology, Dr Mehta's Hospitals, Global Campus, Poonamalle High Road, Velappanchavadi, Thiruverkadu, Chennai -600077 Tamilnadu, India.² Department of Cardiology, Mt Sinai Hospital, New York, USA.³ Department of Cardiology, Karuna Medical College, Perumatty, Kerala-678103, India.⁴ Department of Cardiology, Hindu Mission Hospital, Tambaram, Chennai, Tamil Nadu, India.**Citation:** Veeraraghavan S, Raj Kidambi B, Unnikrishnan S, Balakrishnan K. Successful Reattempt of Percutaneous Balloon Mitral Valvotomy Using Reverse-Loop Entry Technique. Res Heart Yield Transl Med 2025; 20(4):329-331.**Article info:****Received:** 30 Aug. 2025**Revised:** 15 Sep. 2025**Accepted:** 25 Sep. 2025*** Corresponding Author:**

Sriram Veeraraghavan
Professor and Consultant Cardiologist,
Department of Cardiology,
Dr Mehta's Hospitals, Global Campus,
Poonamalle High Rd, Velappanchavadi,
Chennai 600077, Tamil Nadu, India.
Tel: +91 8105 970 705
Email: srivats.007.2003@gmail.com

Keywords: Severe Mitral Stenosis; BMV; Dilated LA; Reverse Loop; Trans-Septal Puncture; Giant Left Atrium; Rheumatic Mitral Stenosis

A 32-year-old woman with severe rheumatic mitral stenosis, atrial fibrillation, and New York Heart Association (NYHA) class 3 symptoms was Referred to our hospital for surgical intervention following a failed balloon mitral valvuloplasty (BMV) attempt.

The initial failure occurred because of the inability to advance the balloon across the heavily stenosed mitral valve. On 2D echocardiography, the left atrium (LA) was massively dilated, measuring 12×13 cm, with a mitral valve area (MVA) of 0.8 cm² and moderate subvalvular involvement. A transesophageal echocardiogram (TEE) confirmed these findings and revealed spontaneous echo contrast (SEC) in the LA without evidence of thrombus, as well as a substantial septal bulge into the right atrium. The 3D TEE-derived MVA was 0.68 cm² (Figure 1A-E). The mean transmitral valve gradient was 24 mm Hg, confirming the severity of the stenosis.

After detailed counseling and informed consent, a second BMV attempt was planned via a modified approach. The septal puncture was moderately challenging due to posterior septal displacement from the giant LA. Transseptal access was obtained using combined fluoroscopic and TEE guidance, with TEE aiding in optimal tenting and needle trajectory. Immediately after successful septal puncture, intravenous unfractionated heparin (70 units/kg) was administered, targeting an ACT greater than 250 seconds during all left atrial instrumentation. To navigate the challenging anatomy and account for the initial failed attempt, we created a reverse loop using a standard coiled-tip J-shaped Inoue guidewire without an alternative wire. This loop facilitated reverse-loop entry across the stenotic mitral valve into the left ventricle (LV) (Figure 1F). A 26 mm Accura balloon (Vascular Concepts, UK)

was selected using the Hung formula for optimal sizing. The balloon was advanced over the looped wire, and the reverse loop was maintained on the flexible balloon shaft with support from the roof and floor of the dilated LA. Once the balloon tip was positioned near the mitral valve, the wire was removed, and a metallic LV entry stylet was introduced into the balloon and retracted 1 to 2 cm. When characteristic bobbing was observed, the balloon catheter was advanced into the LV.

Once in the LV, the distal part of the balloon was inflated, and the assembly was retracted until it anchored at the mitral valve (Figure 1G). The redundant loop in the LA was straightened by retracting the balloon, and full inflation was performed (Figure 1H) (Video 1). Valvulotomy substantially reduced LA pressure to 9 mm Hg and increased MVA to 1.9 cm², with mild mitral regurgitation.

In rheumatic mitral stenosis with a giant LA, distortion of the interatrial septum is common and poses substantial technical challenges during septal puncture.¹ The septum often bulges into the right atrium because of elevated LA pressure, resulting in a flatter and more horizontally oriented fossa ovalis. These anatomic changes complicate conventional puncture techniques, often leading to septal dissection or catch, or failure to advance the balloon. Modified techniques, such as the reverse-loop method, over-the-wire strategies, or double-balloon techniques, can be considered when standard approaches fail.^{2,3} In this case, the combination of a giant LA and septal catch likely contributed to the initial failure. The reverse loop provided necessary balloon support to cross the mitral valve and complete BMV. The loop provided stability by anchoring the balloon to the LA floor.⁴ The technique is useful for overcoming anatomic obstacles in patients with advanced rheumatic heart disease.

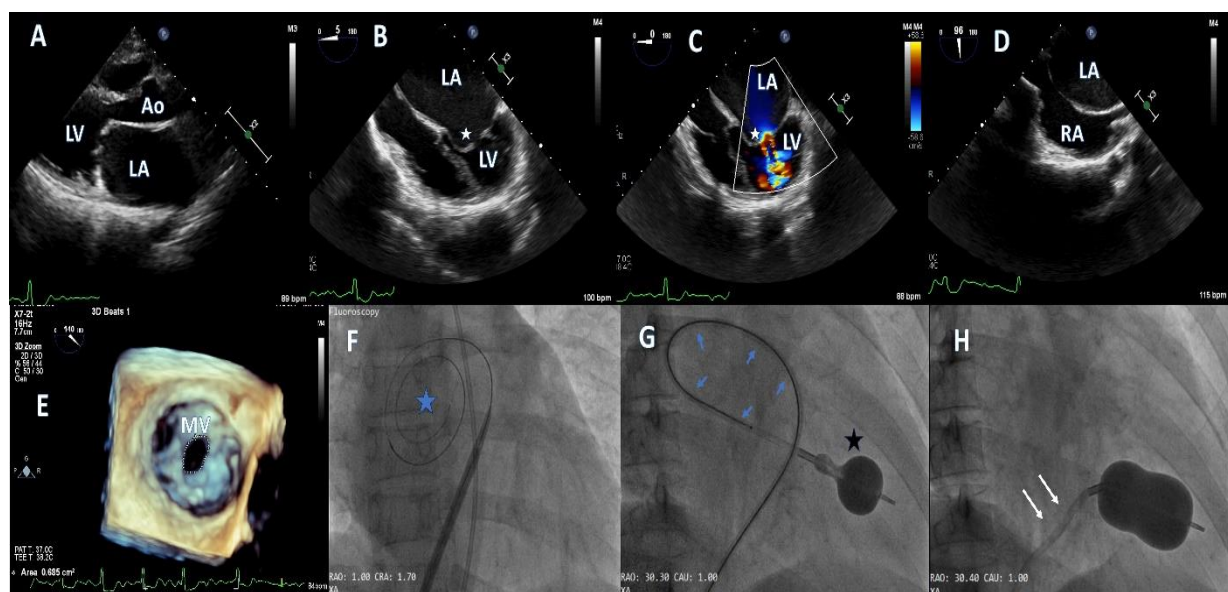


Figure 1.A-E: ECHOCARDIOGRAPHIC IMAGES

A: Transthoracic echocardiogram (TTE) in PLAX view showing dilated LA and doming anterior mitral leaflet suggestive of mitral stenosis.

B: 2D- Transesophageal echocardiogram (TEE) in the four-chamber view showing doming anterior mitral leaflet, stenotic mitral valve (white star), and spontaneous echo contrast (SEC) in the dilated left atrium (LA).

C: 2D-TEE with Color Doppler across the stenotic mitral valve (white star) showing turbulent flow and trivial mitral regurgitation.

D: 2D-TEE in the bicaval view showing the interatrial septum bulging into the right atrium (RA) with Spontaneous Echo Contrast (SEC) because of the dilated LA.

E: 3D-TEE showing the narrowed mitral valve orifice and severe mitral stenosis. Mitral valve area is 0.68 cm².

Figure1. F-H: FLUOROSCOPIC IMAGES DURING BALLOON MITRAL VALVOTOMY (BMV)

F: Fluoroscopic image showing the coiled guidewire (blue star) in the left atrium (LA) rotated counterclockwise within the dilated LA, showing the spatial extent of the chamber and septal displacement.

G: Fluoroscopic image showing the counterclockwise-loop technique for left ventricular (LV) entry, with the balloon shaft and stylet forming a reverse loop (blue arrows) in the large LA, providing support for advancing the Accura balloon (black star) into the mitral valve.

H: Fluoroscopic image showing reduction of the redundant loop (white arrows) as the balloon is anchored and dilated across the mitral valve in the final stages of valvotomy.

LA -Left atrium; LV - Left Ventricle; RA - Right atrium; MV - Mitral valve; Ao- Aorta

References

- Vijayvergiya R, Budhakoty S, Kasinadhuni G, Kanabar K. Reverse-Loop Technique for Percutaneous Transvenous Mitral Commissurotomy in a Patient With Huge Left Atrium. *J Invasive Cardiol*. 2019 Dec;31(12):E397.
- Sinha S, Razi M, Aggarwal P, Abhishek N, et al. Percutaneous balloon mitral valvuloplasty (BMV) in severe mitral stenosis with giant, aneurysmal left atrium (LA) using modified hairpin loop entry — challenges and technical considerations. *Folia Cardiol*. 2016.
- Lin Z. Clinical study of percutaneous balloon mitral valvuloplasty on severe rheumatic mitral stenosis accompanied with giant left atrium. *J Clin Cardiol*. 2011.
- Qi L. 20 Cases Report on Percutaneous Balloon Mitral Valvuloplasty with Very Large Left Atrial Dimension. *J Clin Med Off*. 2002.