

Isolated Chronic Inflammation in the Posterior Mitral Annulus

Ali Hosseinsabet, MD*, Sohyl Mansorian, MD, Maryam Sotoudeh Anvary, MD

Tehran Heart Center, Tehran University of Medical Sciences, Tehran, Iran.

A 56-year-old patient presented to the outpatient clinic with dyspnea on exertion (functional class II) of several months' duration. Physical examinations were unremarkable except for a systolic murmur in the apex. Also, electrocardiography was unremarkable. Transthoracic and transesophageal echocardiographic examinations revealed moderate to severe mitral regurgitation and an echo-free space (4×2 cm) with an echogenic margin in the posterior mitral annulus (Figure 1, Videos 1-3). According to these findings, the patient was referred for surgery. In surgery, the posterior mitral annulus contained a cystic mass filled with a yellow fluid. After the aspiration of this fluid and the removal of this cystic mass, this space was repaired and mitral valve replacement with a mechanical bileaflet prosthesis was done. Fluid culture was negative for microorganisms. The Zill-Nelson staining for mycobacterium tuberculosis was negative. Pathological examination of the fluid and the mass margin showed degenerative cells and chronic inflammation, respectively. Serology test for hydatid cysts was negative. Chronic inflammation containing degenerative cells and presenting as a cystic mass in the posterior mitral annulus is rare. At patient presentation, we found no specific etiology for this inflammation. Accordingly, this isolated chronic inflammation can be the cause of mitral regurgitation as a rare etiology.

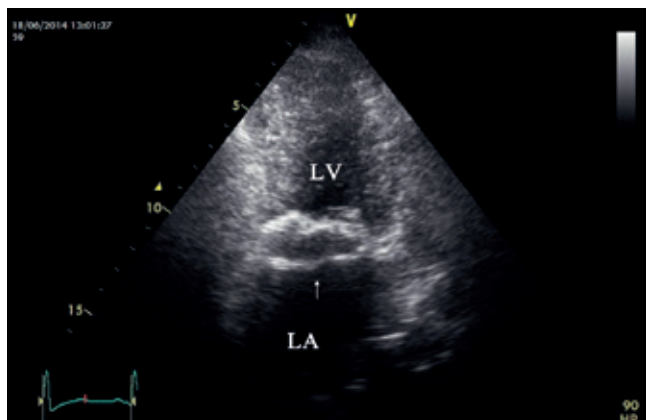


Figure 1. A

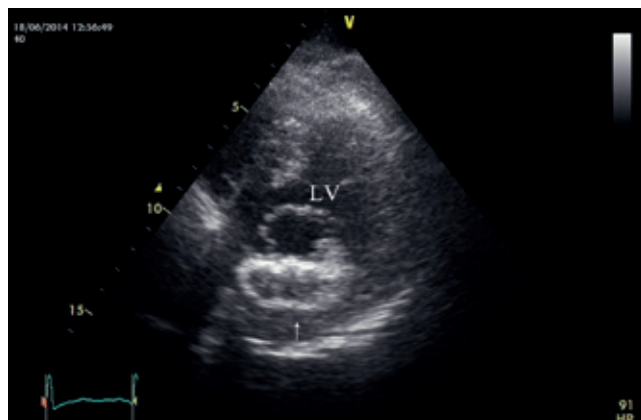

Figure 1. B

Figure 1. Echo-free space (arrow) in the posterior mitral annulus in the apical two-chamber view (A) and parasternal short-axis view (B).
LA, Left atrium; LV, Left ventricle

J Teh Univ Heart Ctr 2016;11(2):102-103

This paper should be cited as: Hosseinsabet A, Mansorian S, Sotoudeh Anvary M. Isolated Chronic Inflammation in the Posterior Mitral Annulus. *J Teh Univ Heart Ctr 2016;11(2):102-103.*

Keywords: Mitral valve • Inflammation • Echocardiography

*Corresponding Author: Ali Hosseinsabet, Assistant Professor of Cardiology, Tehran Heart Center, North Karegar Street, Tehran, Iran. 1411713138. Tel: +98 21 88029731. Fax: +98 21 88029731. E-mail: ali_hosseinsabet@yahoo.com.



To watch the following videos, please refer to the relevant URLs:

Video 1. Echo-free space in the posterior mitral annulus in the apical two-chamber view

URL: <http://jthc.tums.ac.ir/index.php/jthc/editor/downloadFile/588/1162>

Video 2. Echo-free space in the posterior mitral annulus in the parasternal short-axis view

URL: <http://jthc.tums.ac.ir/index.php/jthc/editor/downloadFile/588/1163>

Video 3. Echo-free space in the posterior mitral annulus in transesophageal echocardiography (129°)

URL: <http://jthc.tums.ac.ir/index.php/jthc/editor/downloadFile/588/1165>