



Incidentally Detected Sternal Foramen during an Urgent Surgical Revascularization: A Case Report

Elif Coşkun Sungur, MD*, Ufuk Tütün, MD, PhD, Anıl Tekin, MD

Department of Cardiovascular Surgery, Faculty of Medicine, Bulent Ecevit University, Zonguldak, Turkey.

Received 25 September 2018; Accepted 06 February 2020

Abstract

The sternal foramen is an anatomical variation at the lower third of the sternum which carries the risk of life-threatening complications such as pneumothorax. It is usually asymptomatic and can be misinterpreted as an acquired lesion. The sternum is close to the mediastinal structures; the sternal foramen, thus, leaves the lung, heart, and great vessels unprotected during invasive procedures. A 61-year-old male patient was admitted to our emergency department with sudden-onset chest pain. Acute coronary syndrome was diagnosed by the cardiology department. Coronary angiography confirmed the diagnosis of coronary artery disease, and the patient underwent urgent coronary artery bypass grafting. During the exploration, sternotomy was performed with a proper incision. Two sternal images were obtained via the median incision, and a sternal foramen was detected intraoperatively. To the best of our knowledge, this is the first case of sternotomy to undergo open-heart surgery for coronary heart disease and to be diagnosed with the sternal foramen intraoperatively. It is of vital importance that surgeons and interventionists recognize the sternal foramen, which leaves the mediastinal structures unprotected, and take early precautions.

J Teh Univ Heart Ctr 2020;15(2):81-83

This paper should be cited as: Coşkun Sungur E, Tütün U, Tekin A. Incidentally Detected Sternal Foramen during an Urgent Surgical Revascularization: A Case Report. *J Teh Univ Heart Ctr* 2020;15(2):81-83.

Keywords: Anatomic variation; Sternotomy; Coronary artery disease

Introduction

The ossification centers in the manubrium generally merge before birth. Two or more ossification centers develop in each segment of the mesosternum, known as sternebra. Calcification and fusion in the segments of the sternal body usually occur at the age of 25 years.¹ Failure of the developmental process may lead to sternal variations and anomalies.²⁻⁴ The sternal foramen (SF) is a specific anatomic variation with clinical relevance in that it leaves the heart and great vessels unprotected. Herein, we report a case of sternotomy that underwent open-heart surgery for coronary

heart disease and was diagnosed with the SF intraoperatively.

Case Report

A 61-year-old man was admitted to our emergency department with sudden-onset chest pain. The patient was conscious. His past medical history was nonspecific for coronary artery disease, except for smoking history and essential hypertension. He was taking carvedilol (625 mg daily), cilazapril (5 mg daily), irbesartan/hydrochlorothiazide combination (150 mg/12.5 mg daily), and clopidogrel (75 mg

*Corresponding Author: **Elif Coşkun Sungur**, Assistant Professor of Cardiac Surgery, Department of Cardiovascular Surgery, Ankara City Hospital, Universiteler Mahallesi 1604, Cadde No. 9, Cankaya, Ankara, Turkey. 06800. Tel: +90 312 5526000. Fax: +90 312 5529982. E-mail: drelfo@gmail.com.



daily). He was hemodynamically stable at presentation with a heart rate of 70 beats per minute, blood pressure of 145/95 mmHg, and a respiratory rate of 14 breaths per minute. Electrocardiography and laboratory studies were obtained; the former showed ST-segment depressions in the inferior leads and the latter demonstrated a high cardiac troponin T level (1.28 ng/mL, normal range between 0 and 0.03 ng/mL). Transthoracic echocardiography revealed hypokinesia in the left ventricular wall. With an initial diagnosis of non-ST-elevation myocardial infarction, an infusion of a 5000 IU/mL solution of heparin sodium (intravenous 18 IU/kg) and a 1 mg/mL solution of glyceryl trinitrate (intravenous 0.5 µg/kg/min) was started.

Acute coronary syndrome was diagnosed by the cardiology department, and an urgent selective coronary angiography was planned. The coronary angiography confirmed the diagnosis of coronary artery disease, and the patient underwent urgent coronary artery bypass grafting. As urgent revascularization was planned, no advanced imaging modalities were used preoperatively, except for chest X-ray (Figure 1). Written informed consent was obtained from the patient, and the patient was prepared for the operation.

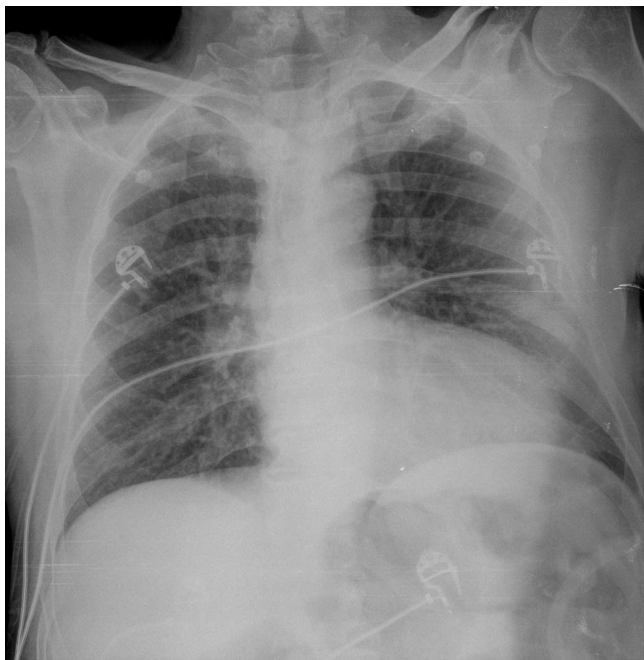


Figure 1. Chest X-ray of the patient in the posteroanterior view, failing to demonstrate the foramen

Under aseptic conditions and general anesthesia, sternotomy was performed with a proper incision. The manubrium and xiphoid parts of the sternum were dissected beneath the tissues, and median sternotomy was applied. No intraoperative complication was observed. During the exploration, no cortical integrity in the fourth and fifth intercostal spaces in the corpus region, which is close to the xiphoid process, was recognized. The sternal cortex

terminated with smooth margins. Two sternal images were obtained via the median incision, and an SF was detected intraoperatively (Figure 2). Through an appropriate imaging modality, surgery was continued. Five-vessel coronary artery bypass grafting was performed, and the total duration of cardiopulmonary bypass and aortic cross-clamp time was 159 minutes and 86 minutes, respectively. The patient was intubated and transferred to the intensive care unit under the intra-aortic balloon pump and inotropic support. He was taken to the ward on postoperative day 3 and discharged uneventfully on postoperative day 7. On 3D computed tomography imaging at 1 month postoperatively, the SF was visualized (Figure 3). The patient has been followed without any problem in the first postoperative year.

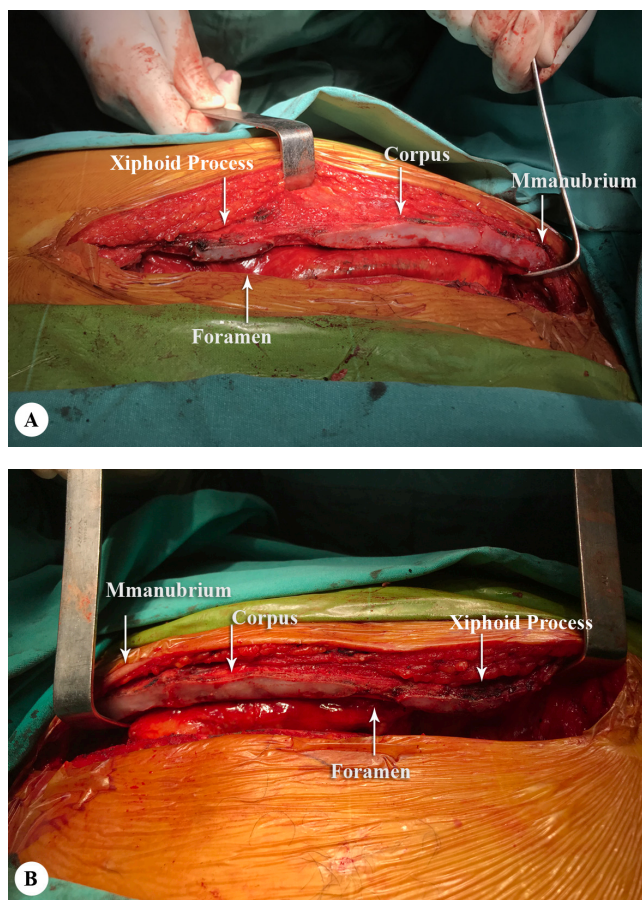


Figure 2. A) Right part of the mid-sagittal image after median sternotomy, showing the foramen and the anatomical parts of the sternum (arrows), B) Left part of the mid-sagittal image after median sternotomy, showing the foramen and the anatomical parts of the sternum (arrows)

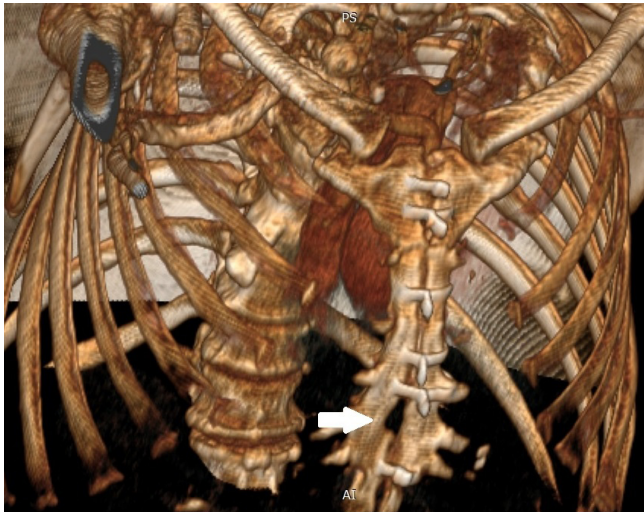


Figure 3. Postoperative anterior oblique plane 3D computed tomography image, showing the foramen (arrow)

Discussion

The SF is mostly incidentally diagnosed in imaging studies or post-mortem examinations. The incidence of the SF is between 4.3% and 4.5% in the imaging studies.^{2, 5, 6} In the autopsy series, the incidence of the SF is higher, ranging between 6.6% and 6.7%.^{3, 4}

The SF is usually asymptomatic, and physical examinations are often unremarkable insofar as the foramen is mainly full of dense connective tissues.¹ Similarly, physical examinations revealed nonspecific findings in our case. Computed tomography is often helpful in identifying the SF.^{2, 7} However, only chest X-ray scans were available in our case, and no thoracic computed tomography had been performed previously.

In the SF diagnosis, it is of utmost importance to recognize sternal variations and anomalies as assessed by imaging studies and to distinguish the SF from traumatic fissures/fractures or lytic lesions.^{2, 7, 8} These lytic lesions represent secondary neoplastic lesions or metastatic foci. In a study, the presence of the SF was confirmed in 43.1% of the patients who underwent sternal uptake on bone scintigraphy.⁸ In that study, 24% of the patients with the SF showed normal sternal scintigraphy findings. In both conditions, however, lesions are characterized by irregular anatomic and radiological margins and cortical irregularity, cortical expansion, and the lack of soft tissue mass.⁷ Likewise, our patient was diagnosed with the SF, even if it was late, based on the lack of cortical regularity and sternal continuity as assessed by macroscopic examinations following sternotomy. As we did not recognize the SF during sternotomy, we used a sternal saw above the pericardium. However, no complication was seen. In the literature, on the other hand, fatal cardiac tamponade due to sternal bone marrow aspiration in patients undergoing bone

marrow aspiration or acupuncture has been reported.⁹⁻¹¹

Conclusion

To the best of our knowledge, this is the first case of sternotomy to undergo open-heart surgery for coronary heart disease and to be diagnosed with the SF intraoperatively. Clinicians, particularly cardiovascular surgeons, should recognize the SF to prevent life-threatening complications. In addition, in large defects that can be overlooked preoperatively, the SF may pose certain challenges to surgeons during sternal closure.

References

1. Babinski MA, de Lemos L, Babinski MS, Gonçalves MV, De Paula RC, Fernandes RM. Frequency of sternal foramen evaluated by MDCT: a minor variation of great relevance. *Surg Radiol Anat* 2015;37:287-291.
2. Yekeler E, Tunaci M, Tunaci A, Dursun M, Acunas G. Frequency of sternal variations and anomalies evaluated by MDCT. *AJR Am J Roentgenol* 2006;186:956-960.
3. Cooper PD, Stewart JH, McCormick WF. Development and morphology of the sternal foramen. *Am J Forensic Med Pathol* 1988;9:342-347.
4. Moore MK, Stewart JH, McCormick WF. Anomalies of the human chest plate area. Radiographic findings in a large autopsy population. *Am J Forensic Med Pathol* 1988;9:348-354.
5. Gossner J. Relationship of sternal foramina to vital structures of the chest: a computed tomographic study. *Anat Res Int* 2013;2013:780193.
6. Stark P. Midline sternal foramen: CT demonstration. *J Comput Assist Tomogr* 1985;9:489-490.
7. Duraikannu C, Noronha OV, Sundarajan P. MDCT evaluation of sternal variations: pictorial essay. *Indian J Radiol Imaging* 2016;26:185-194.
8. Ishii S, Shishido F, Miyajima M, Sakuma K, Shigihara T, Kikuchi K, Nakajima M. Causes of photopenic defects in the lower sternum on bone scintigraphy and correlation with multidetector CT. *Clin Nucl Med* 2011;36:355-358.
9. van Marum RJ, te Velde L. Cardiac tamponade following sternal puncture in two patients. *Neth J Med* 2001;59:39-40.
10. Bhootra BL. Fatality following a sternal bone marrow aspiration procedure: a case report. *Med Sci Law* 2004;44:170-172.
11. Halvorsen TB, Anda SS, Naess AB, Levang OW. Fatal cardiac tamponade after acupuncture through congenital sternal foramen. *Lancet* 1995;345:1175.